



RESEARCH ARTICLE

Effects of White Ginger Phytosome Gel on Wound Healing in Mice: Studies on TGF- β 1, VEGF, and Tissue Growth

Nielma Auliah^{1,2*}, Sartini³, Khairuddin Djawad^{4,5}, Irfan Idris², Mustofa⁶, Gemini Alam⁷, Upik A. Miskad^{8,9}, Andriany Qanitha^{10,11}

¹Fakultas Farmasi, Megarezky University, Makassar, South Sulawesi, Indonesia

²Fakultas Kedokteran, Hasanuddin University, Makassar, South Sulawesi, Indonesia

³Department of Pharmacy, Faculty of Pharmacy, Hasanuddin University, Tamalanrea, Makassar, Indonesia

⁴Department of Dermatology and Venereology, Faculty of Medicine, University of Hasanuddin, Makassar, Indonesia

⁵Rumah Sakit Wahidin Sudirohusodo, Makassar, Indonesia

⁶Department of Pharmacology and Therapy, Faculty of Medicine, Public Health, and Nursing, Universitas Gadjah Mada, Indonesia

⁷Department of Pharmacognosy-Phytochemistry, Faculty of Pharmacy, Hasanuddin University, Makassar, Indonesia

⁸Department of Anatomical Pathology, Faculty of Medicine, Hasanuddin University, Makassar, Indonesia

⁹Anatomical Pathology Laboratory, Hasanuddin University Hospital, Makassar, Indonesia

¹⁰Department of Physiology, Faculty of Medicine, Hasanuddin University, Makassar, Indonesia

¹¹Department of Cardiology and Vascular Medicine, Faculty of Medicine, Hasanuddin University, Makassar, Indonesia

ARTICLE INFO	ABSTRACT
Received: Dec 29, 2024	<p>Temu Putih rhizome contains bioactive compounds such as flavonoids, polyphenols, curcuminoids, terpenoids and essential oils that have antioxidant, anti-inflammatory, anticancer, and antimicrobial activities. This study aims to formulate and determine the effectiveness of Temu Putih extract in vivo in Wistar rats. Temu Putih rhizome was macerated with ethanol, then the thick extract was phytochemical screening and determination of polyphenol content, then made in the form of phytosomes by mixing extracts and phosphatidylcholine. The phytosomes formed were tested macro and microscopically. Phytosomes were then made into gel preparations and tested for physical stability including organoleptics, pH, spreadability, and viscosity. The effectiveness test of the phytosome gel was carried out on excision wounds on the back of rats. This experimental study focuses on the treatment of male Wistar using wounds with a post-test with control group design. Animals were divided into five groups, each group consisting of 15 male Wistars. The results showed that the ethanol extract of temu putih contains flavonoids, saponins, alkaloids, and tannins. The polyphenol content contained in the extract was 1.639. The sorption percentage of phytosomes 0.5 was 85.64 with a particle size of 432.995 nm. Stability test results of phytosome gel preparation showed physically and chemically stable. The decrease in diameter from day 3 to day 11 showed a significant decrease in several treatment groups with a p value <0.05. Histopathology results showed for the granulation category showed the formation of granulation tissue on day 11, a decrease in inflammatory cells and the formation of epithelialized tissue showed positive results. Phytosome gel preparation of white temu extract (<i>Curcuma zedoaria</i> Rosc.) provides an effect on wound healing and has the potential to be developed into a product.</p>
Accepted: Feb 7, 2025	
Keywords	
Temu putih extract	
Wound	
TGF β 1	
VEGF	
Granulation	
Epithelialization	
*Corresponding Author:	
nielmaauliah@gmail.com	

INTRODUCTION

Skin wound healing involves cell collaboration and regeneration, starting with inflammation. This process replaces specialized structures through collagen deposition and regeneration. Wounds can impair the skin's protective function, affect muscles, bones and nerves, and potentially cause damage to other tissues (Risal Wintoko, 2020).

One type of wound is an excision wound, which is caused by cutting the tissue by a sharp object (Cahya et al., 2020). Excision wounds are included in open wounds and occupy the top three types of wounds felt by residents at 22.0%, with the prevalence of wounds in West Sumatra continuing to increase from 5.8% in the 2013 riskesdas to 8.7% in the 2018 riskesdas (Kemenkes RI, 2018) (Ifmaily et al., 2023).

Wound healing is a complex process of human physiology involving cellular and molecular interactions (Prasetyono, 2009). It begins immediately after injury and consists of regeneration and repair processes. The process is divided into three phases: inflammation, proliferation and angiogenesis, and tissue remodeling. Wound healing aims to restore skin integrity, reorganize, resurface, and provide tensile strength (Falanga, 2005).

Acute wound healing depends on the balance of cytokines, mitogenic activity, proinflammatory and anti-inflammatory factors, and proteases (Lobman, Schultz & Lehnert, 2005) (Alexiadou & Doupis, 2012). Growth factors, such as Epidermal Growth Factor (EGF), Fibroblast Growth Factor (FGF), Insulin-like Growth Factor (IGF), Keratinocyte Growth Factor (KGF), Platelet-Derived Growth Factor (PDGF), Transforming Growth Factor (TGF), and Vascular Endothelial Growth Factor (VEGF) (Martil-carvajal et al., 2010), are essential in wound healing. TGF- β 1 is essential for inflammation, angiogenesis, re-epithelialization, and regeneration of connective tissue, initiates granulation tissue formation, and regulates the angiogenic growth factor VEGF (Barrientos et al., 2008).

Herbal plants with wound healing activity contain active compounds such as flavonoids, alkaloids, tannins, saponins, terpenoids, and steroids. Flavonoids protect compounds against reperfusion, antioxidants reduce lipid peroxidation, and astringents and antimicrobials promote wound contraction and epithelialization. Alkaloids damage bacterial cell walls, saponins accelerate hemolytic activity, and tannins promote scar tissue formation and contraction. Terpenoids prevent cell necrosis, astringents and antimicrobials promote wound contraction, and steroids promote epithelialization (Dewi & Wicaksono, 2020).

Temu putih (*Curcuma zedoaria* Rosc.) is empirically used by the Indonesian people as a stomatikum, carminativum, tonicum, snake bite antidote, treatment of wounds and ulcers (Handajani, 2013). Temu putih contains curcuminoids, essential oils and polysaccharides (Lianah, 2019). Secondary metabolite compounds in white temu contain flavonoids and saponins (Wati et al., 2018).

White turmeric rhizomes are rich in bioactive compounds, including flavonoids, polyphenols, curcuminoids, terpenoids, and essential oils, and have antioxidant, anti-inflammatory, anticancer, and antimicrobial properties (Gafar & Agustini, 2020) (Pimrat et al., 2021). Its antioxidant activity is more effective than ascorbic acid and similar to BHA and α -tocopherol (Kaushik et al., 2021) (Kg Ileperuma et al., 2022). Steamed rhizomes have the highest curcuminoid content and antimicrobial activity against *Staphylococcus aureus*, MRSA, and *Candida albicans*. Various mono formulations of herbal C (Barus, 2021) (Wulandari & Puspitasari, 2019). zedoaria, including MHF-A, MHF-C, and MHF-D, can reduce leg swelling and inhibit inflammasomes (Desmiaty et al., 2020). Ethanol extract of white turmeric has burn wound healing activity, with the best concentration for leukocyte count being 15%. White turmeric leaf extract gel has anti-inflammatory effects, with concentrations of 2.5%, 5%, and 10% providing anti-inflammatory effects. zedoaria has strong antioxidant activity of 49.72 ppm.

Drug delivery systems, both orally and transdermally, can increase the bioavailability of drugs by encasing the active ingredients in a lipid layer (Putri Febrianti et al., 2023). This facilitates the entry of phytoconstituents into the skin and targets inflammatory targets, provides chemical bonding and

increases the stability of the extract (Indalifiany et al., 2022) (Putri Febrianti et al., 2023). Vesicular delivery systems, consisting of liposomes, ethosomes, transfersomes and phytosomes, are commonly used and have a significant impact on drug delivery. Phytosomes, which contain active ingredients from plants, form drug complexes in phospholipids, improving drug absorption and efficacy (Aprini, Amelia & Mita, 2021). Phytosome compounds are superior due to the presence of phytoconstituents that combine with phospholipid molecules (Haruni et al., 2019) (Putri Febrianti et al., 2023).

Based on previous research, the researchers wanted to conduct research related to the effect of phytosome gel preparations and temu putih ethanol extract gel (*Curcuma zedoaria* Rosc) on the dynamics of Transforming Growth Factor (TGF β 1), Vascular Endothelial Growth Factor (VEGF), Granulation, and Tissue Epithelialization in the Acute Wound Healing Process in Mouse Models.

MATERIAL AND METHODS

Research Design

This experimental study focused on the treatment of male Wistar using wounds with a post-test with control group design. Animals were divided into five groups, each group consisting of 15 male Wistars. Wounds were treated with a variety of treatments, including a base gel, Bioplacenton, a phytosome gel of Temu Putih extract, a gel preparation of Temu Putih extract. Biomarkers such as TGF β 1 and VEGF were measured in each group. Histopathology measurements were also taken to assess the effect of the gel preparations on wound healing. The study was conducted on three different days, with each group studied.

Time and Place of Study

The research, which was conducted between February and October 2024, included extraction of white turmeric rhizomes, preparation of phytosomes and gel preparations, polyphenol testing, particle size measurement, wound intervention, testing TGF β 1 and VEGF levels, and histopathology examination.

Tools and Materials

This study used various tools including ELISA, microscope, PSA, UV-VIS spectrophotometer, and maceration equipment. Sample materials included temu putih rhizomes, distilled water, ethanol, gel base, TGF β 1 and VEGF KIT reagents, and various chemicals.

Research Procedures

1. White temu (*Curcuma zedoaria*) rhizomes were obtained in Maros, washed, cut, dried, mashed, weighed, sieved, and sonicated before weighing, sieving, and sonicating to obtain samples.
2. The white temu (*Curcuma zedoaria*) rhizome extract was prepared through maceration, extraction, filter paper separation, rotary evaporation, and weighing, and the impregnation calculation was carried out after the thick extract was obtained.
3. Phytochemical screening of White temu (*Curcuma zedoaria*) Rhizome Extract involves the identification of flavonoids, tannins, saponins, and alkaloids. Flavonoids were identified by browning the amyl alcohol layer. Tannins are identified by producing a dark blue or green color. Saponins are detected by forming a stable foam. Alkaloids are identified by forming a white precipitate when reacting with Mayer's reagent.
4. Ethanol extract of white temu rhizome was prepared by mixing phosphatidylcholine with distilled water and dissolved in 96% ethanol. The mixture was stirred, evaporated, and stored in a desiccator for 24 hours. The thin layer of phytosomes was hydrated with distilled water in a rotary evaporator for 20 minutes. (Indalifiany et al., 2022).
5. The morphology of the phytosomes was observed using a microscope. The adsorption efficiency was determined by centrifuging the phytosomes for 1 hour and analyzing the

absorbance of the supernatant. Particle size and polydispersity index were determined using a dynamic light scattering type Particle Size Analyzer (PSA).

6. Preparation of phytosome gel included weighing of ingredients, heating of distilled water, preparation of HPMC, addition of propylene glycol, and DMDM hydantoin, stirring until homogeneous, then the mixture was transferred into a gel container.

Treatment of Test Animals

This study involved 75 male Wistar albino rats aged 4-6 weeks, placed in wire cages with a density of 3 rats per cage. Wistar rats were fed 300 grams/hour/mouse and maintained in a stable environment with room temperature, humidity, and light. Wistars adapted to the cage and environment for 3-6 days prior to the intervention. Wistars were weighed, GDS measurements were taken, and sent to five groups of 15 rats each. Wistars were excised on the left and right dorsal areas, cleaned, anesthetized, and excised. Wistars died every 3 days, 7 days, and 11 days, and were buried in the ground after death. Acute wound modeling involved dorsal hair removal, disinfection of the area, and anesthetization of the animal. Topical administration techniques included application of the base gel, Bioplacenton, white turmeric extract phytosome gel, and a combination of these treatments. The animals underwent histopathological examination and TGF- β 1 and VEGF assays using the ELISA method. Wistar diameter was measured before sacrifice on days 3, 7, and 11.

Histopathologic Examination of Wound Tissue

Skin tissue samples were obtained via biopsy for histopathological examination. The wound tissue was cut into squares and fixed in 10% formalin. Slices embedded in paraffin were serially cut and stained with hematoxylin and eosin. Tissue granulation thickness and connective tissue area were measured using a JVC video micrometer. Tissue epithelialization was measured using a microtome and rehydration process. Tissues were viewed under an electron microscope at 200-400 magnification. Both measurements were performed in a 10% normal buffered formalin environment.

Data Analysis

Data were analyzed using SPSS with a significance limit of $p < 0.05$. Analysis used nonparametric tests including Friedman test, Maan Witney test, and Kruskal-Wallis test to test the relationship between TGF- β 1 levels, granulation score, tissue epithelialization score, wound diameter, and granulation in Wistar with acute wound model.

Research Ethics

This study was conducted after obtaining a recommendation for approval from the Health Research Ethics Committee of the Faculty of Medicine, Hasanuddin University with number 836/UN4.6.4.5.31/PP36/2024.

RESULTS

1. Extraction of White Temu (*Curcuma zedoaria*) Rhizome

Table 1. Rendamen Results

Sample	Solvent type	Sample weight (g)	Weight thickened extract (g)	of %
Temu rhizome White	Etanol 96%	350,49	50,30	14,35

White temu (*Curcuma zedoaria*) rhizome extract as much as 350.49 grams, extracted using the maceration method, with 96% ethanol solvent so that the thick extract obtained is 50.30 grams with a yield of 14.35%.

Table 2. Phytochemical Screening Results of White Temu Rhizome Extract (Curcuma zedoaria)

No.	Chemical Content	Reagent	Results	Description
1.	Flavanoid	Mg + HCL pekat	Brown	+
2.	Saponid	Aquadest	There is Foam	+
3.	Alkaloid	Mayer	White Deposit	+
4.	Tanin	FeCL3	Green	+

Description:




(+) = Positive

(-) = Negative

Table 3. Testing Results of Polyphenol Content of White Temu Rhizome Extract (Curcuma zedoaria)

Sample	Absorbant	Total Polyphenol Concentration of Samples	Mg Sample	Sample Concentration	Total Polyphenol Content of Samples b/b %	Average Total Polyphenol Content of Samples %
Extract 1	0,142	17,462	10,5	1050,0	1,663	1,639
Extract 2	0,138	17,032	10,5	1050,0	1,622	
Extract 3	0,139	17,140	10,5	1050,0	1,632	

Table 4. Phytosome Morphology Observation Results

Formulas	Comparison of Phytoconstituent Concentration Phospholipids	Phytosome Morphology
F1	0,5 : 0,5	
F2	0,5 : 1	
F3	1 : 0,5	

F4	1 : 1	
F5	2 : 1	

Description: Using 100x magnification optical microscope

Table 5. Results of Sorption Percentage

Formulas	Comparison of Phytoconstituent Concentration Phospholipids	Adsorption Efficiency (%)
F1	0,5 : 0,5	85,64%
F2	0,5 : 1	84,21%
F3	1 : 0,5	82,44%
F4	1 : 1	84,62%
F5	2 : 1	82,62%

Description:

Good absorption efficiency values range from 80-100%.

Table 6: Particle size results

Formulas	Comparison of Phyto constituent Concentration : Phospholipids	Particle Size
F1	0,5 : 0,5	432,995 nm

Description:

Good particle size values range from 100-3000 nm.

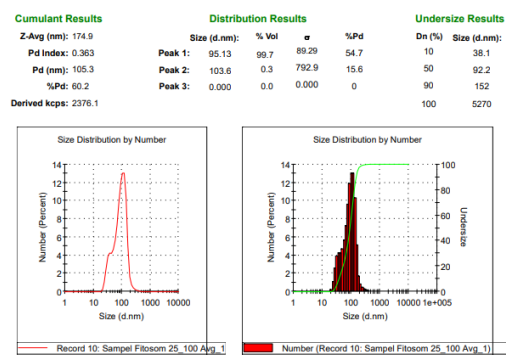


Figure 1. PSA (Particle Size Analyzer) Measurement Results

From the figure above, it can be seen that the Z avg value shows the average particle size in the phytosome sample, which is 174.9 nm, where the average particle size range is in the range of 100-200 nm. While the Pd Index shows the level of particle size distribution of 0.363 (ideally <0.3). The graph shows that the size distribution based on the number of particles shows a peak value of around 100 nm. According to research by Paliwal (2021), emphasizes the importance of size distribution control, where particles with sizes between 50-200 nm are considered ideal for delivery efficiency and biocompatibility.

Table 7. Design of phytosome gel preparation formula and white temu extract gel (Curcuma zedoaria)

Material	Function	Concentration(% b/v)		
		Fitosom	(K-)	(K+)
Fitosom Fosftadilkolin	+Active substance	0,5:0,5	-	Bioplacenton
HPMC	Gelling Agent	1,5%	1,5%	
Propilenglikol	Humektan	5%	5%	
DMDM Hydantoin	Preservative	0,5%	0,5%	
Aquadest	Solvent	ad 100mL	ad 100mL	
Material	Function	Concentration(% b/v)		
		Ekstrak	(K-)	(K+)
White turmeric extract	Active substance	0,5%	-	Bioplacenton
HPMC	Gelling Agent	1,5%	1,5%	
Propilenglikol	Humektan	5%	5%	
DMDM Hydantoin	Preservative	0,5%	0,5%	
Aquadest	Solvent	ad 100mL	ad 100mL	

2. Wound Diameter

The study found that the wound diameter decreased significantly on day 3 after treatment, with the phytosome gel group experiencing the fastest shrinkage. The diameter decreased further on days 7 and 11, with the phytosome gel group showing the greatest decrease. The Friedman statistical test showed significant differences between the treatment groups, with a p value of <0.05.

Table 8. Mean Wound Diameter by Group and Duration of Treatment

Group	Day 0		Day 3		Day 7		Day 11		p*
	N	Media n (min - max)	n	Media n (min - max)	n	Media n (min - max)	n	Media n (min - max)	
Natural healing	5	6,0	5	5,4 (5,4 - 5,8)	5	4,2 (4,1 - 4,4)	5	3,0 (3,0 - 3,2)	0.074
Positive control (Bioplasenton)	5	6,0	5	5,1 (5,0 - 5,5)	5	3,6 (3,5 - 3,8)	5	2,4 (2,4 - 2,6)	0.007
Negative control (Basis gel)	5	6,0	5	5,4 (5,2 - 5,7)	5	3,9 (3,8 - 4,0)	5	3,0 (2,9 - 3,0)	0.007

White Curcuma Extract Phytosome Gel	5	6,0	5	5,0 (4,4 – 5,1)	5	2,9 (2,7 – 3,1)	5	1,5 (0,9 – 2,0)	0.00 7
White Curcuma Extract Gel	5	6,0	5	5,1 (5,0 – 5,2)	5	3,2 (3,1 – 3,3)	5	2,3 (2,0 – 2,5)	0.00 7

3. Differences in Mean Wound Diameter Based on Duration of Treatment

This study found that wound diameter decreased in all groups, with larger mean diameters in the phytosome gel and extract gel groups on days 3 to 7. The largest difference was found in the natural healing group on days 7 to 11, followed by the phytosome group on days 3 to 11.

Table 9. Difference in Mean Wound Diameter Values in Each Treatment Group

Kelompok	Mean Diameter (3-7)	p*	Mean Diameter (7-11)	p*	Mean Diameter (3-11)	p*
Natural healing	7,8	0.016	6,00	0.588	3,80	0.073
Positive control	3,2		5,00		7,20	
Negative control	5,8	0.750	3,30	0.014	3,80	0.074
Positive control	5,2		7,70		7,20	
Ekstrakt Gel	3,4	0.025	3,60	0.034	4,30	0.192
Positive control	7,6		7,40		6,70	
Phytosome Gel	3,5	0.034	6,90	0.129	7,80	0.014
Positive control	7,5		4,10		3,20	

The size of the wound diameter on day 0 to day 14 in all groups can be seen as follows:




Figure 2: Macroscopic view of wound healing stages

On day 0, day 3, day 7, and day 14 based on group A = Natural healing, B = Positive control, C = Negative control, D = White temu phytosome gel, E = White temu extract gel. Based on the figure, the diameter of the wound was reduced from the initial opening of 6 mm and on day 7 the size of the wound diameter was smaller in the phytosome group compared to the control, while on day 11 all groups had experienced wound closure with a very small diameter. The best diameter size was in the phytosome temu putih gel group followed by the extract gel group and the control group.

4. Differences in Granulation in Rats with Acute Treatment Model Based on Duration of Treatment

This study analyzed the granulation scores of various groups on different days after treatment. The natural healing group showed the highest scores in the small category (80%) and medium category (20%), while the control group had the lowest scores (100%). The negative control, phytosome gel, and extract gel groups showed similar scores in the small and medium categories. The Kruskal-Wallis statistical test showed no significant difference between the groups on day 7 ($p < 0.05$). On day 11, all groups showed similar granulation scores in most categories (100%), except for the phytosome gel group.

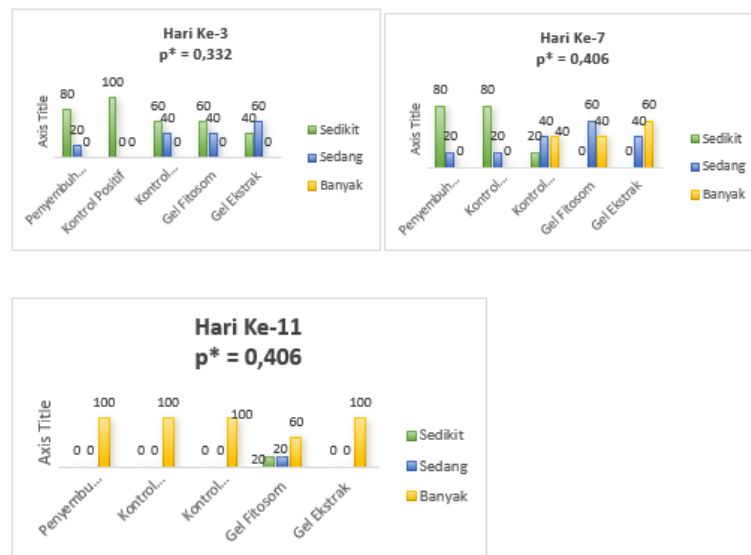


Figure 3: Differences in Granulation Score by Group in Wistar Acute Wounding Model

5. Differences in Epithelialization in Mice with Acute Wounding Model Based on Treatment Duration

This study examined the growth of tissue epithelialization in wound healing, with different treatment groups showing different percentages of epithelialization. The phytosome gel, extract gel, and positive control groups showed 80% and 20% epithelialization, respectively. The natural treatment and negative control groups showed 60% and 40% epithelialization, respectively. On day 7, the percentage of epithelialization changed to 50-90%, with 80% in the natural cure and positive control groups. On day 11, most groups achieved full healing, with no significant difference in the percentage of re-epithelialization.

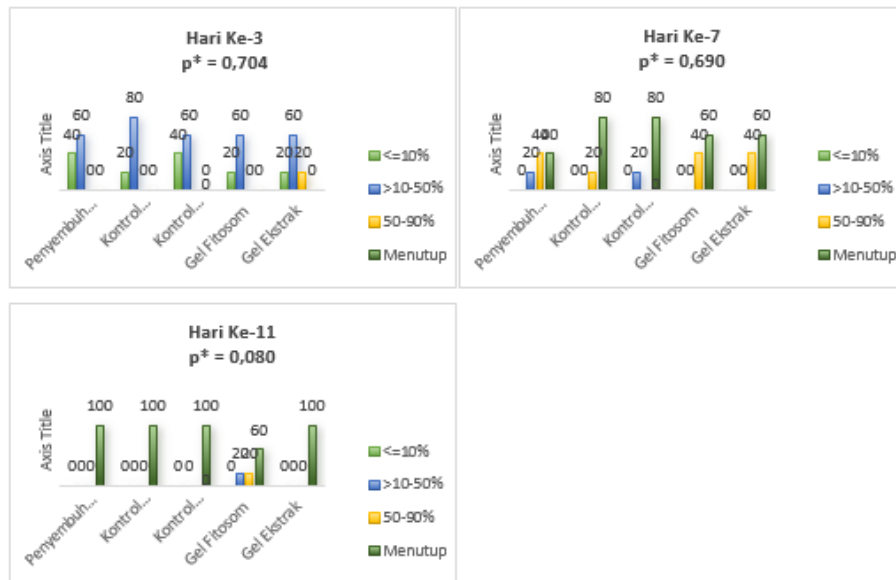


Figure 4. Difference in Epithelialization Score Based on Treatment Duration

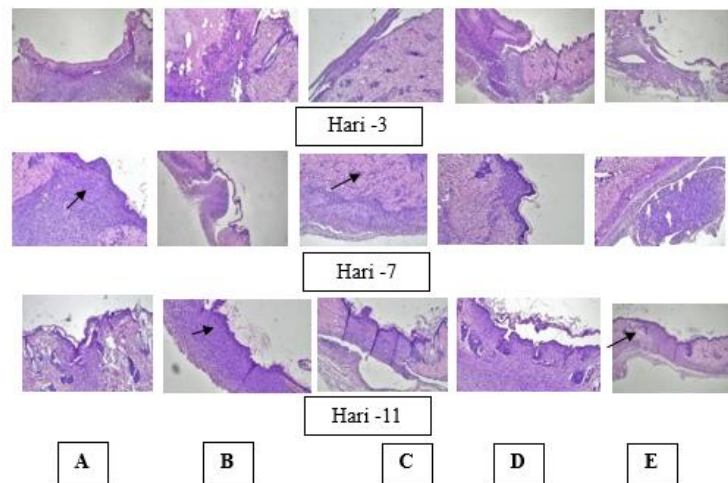


Figure 5: Histopathological features of wound healing stages on day 3, day 7, and day 11 based on group A: natural healing, B: positive control, C: negative control, D: phytosome gel, E: extract gel. Based on histopathological examination with semiquantitative assessment on 3 parameters namely granulation tissue, inflammatory cells, and tissue re-epithelialization.

7. TGF β 1 Levels in Wistar According to Group and Treatment Duration

This study found that TGF levels increased significantly in the phytosome gel group on days 3, 7, and 11, compared to the positive control group. The highest levels were observed in the gel extract group on days 3, 7, and 11, with significant differences in p values.

Table 10. TGF β 1 Levels by Group and Treatment Duration

Group	Day 3		Day 7		Day 11		p*
	n	Median (min - max)	n	Median (min - max)	n	Median (min - max)	
Natural healing	5	474,12 (318,4 - 497,5)	5	466,47 (426,3- 564,6)	5	496,23 (426,3- 564,6)	0.022

Positive control (Bioplasenton)	5	276,48 (177,0 - 319,3)	5	330,13 (123,1- 395,1)	5	407,36 (382,8- 504,2)	0.097
Negative control (Basis gel)	5	494,64 (394,4 - 532,9)	5	448,29 (409,8- 575,8)	5	521,60 (418,4- 665,8)	0.022
White Curcuma Extract Phytosome Gel	5	494,61 (389,2- 526,0)	5	485,89 (382,5- 522,8)	5	572,82 (466,0- 631,4)	0.050
White Curcuma Extract Gel	5	441,28 (210,3 - 588,8)	5	535,32 (335,4- 599,8)	5	630,42 (390,2- 684,0)	0.022

8. VEGF Levels in Wistars Based on Group and Duration of Treatment

This study analyzed VEGF levels in Wistar patients and found that the phytosome gel and white turmeric extract gel groups showed the highest levels. The phytosome group showed more effective treatment in increasing VEGF levels than the other groups. The white turmeric extract group showed more potential to accelerate angiogenesis by increasing VEGF. The natural cure group showed no significant difference.

Table 11. VEGF Levels by Group and Treatment Duration

Group	Day 3		Day 7		Day 11		p*
	n	Median (min - max)	n	Median (min - max)	n	Median (min - max)	
Natural healing	5	638,88 (375,0- 685,8)	5	658,71 (461,9- 736,1)	5	763,25 (475,1- 781,1)	0.097
Positive control (Bioplasenton)	5	604,76 (375,7- 827,6)	5	612,89 (373,5- 851,9)	5	724,95 (645,9- 935,6)	0.015
Negative control (Basis gel)	5	725,12 (669,4- 767,0)	5	749,21 (688,2- 842,3)	5	818,34 (762,1- 861,4)	0.022
White Curcuma Extract Phytosome Gel	5	1097,50 (1094,9- 1262,8)	5	1638,70 (1548,4- 1676,8)	5	1752,40 (1566,2- 1966,9)	0.050
White Curcuma Extract Gel	5	1121,80 (620,2- 1261,8)	5	1157,3 (647,3- 1446,4)	5	1380,2 (661,31- 1566,58)	0.022

Table 11 shows the differences in VEGF levels based on treatment duration (3-7 days, 7-11 days, and 3-11 days) in the various treatment groups. The 7-11 day period showed the greatest increase, indicating a longer healing time for angiogenesis. The phytosome gel group showed the highest growth, indicating its effectiveness in accelerating angiogenesis. The extract gel group showed low improvement at 3-7 days but greater at 7-11 days.

Table 12. Difference in Mean Values of TGF β 1 and VEGF in Each Group Intervention

Group	Mean TGF	Delta TGF (p*)	Mean VEGF	Delta VEGF (p*)
Natural healing	47,49	0,151	10,04	0,114
Fitosom	91,76		55,67	
Positive control	17,38	0,071	17,84	0,190

Phytosome gel	91,76		55,67	
Negative control	48,69	0,151	76,00	0,032
Phytosome gel	91,76		55,67	
Extract gel	14,94	0,548	18,63	0,111
Phytosome gel	91,76		55,67	

DISCUSSION

This study used an experimental design with male mice divided into five groups: natural healing, positive control, negative control, and white turmeric rhizome extract phytosome gel. The aim was to determine the effect of phytosome gel administration of white turmeric rhizome extract on acute wound healing in mice, focusing on increasing TGF- β 1 and VEGF levels, tissue granulation, inflammatory cells, and epithelialization.

Experimental mice were anesthetized with ketamine, and each group was modeled for acute wounds using a 6 mm diameter biopsy stitch. A circular wound model was used to facilitate assessment and preparation for histopathology examination.

Rats with left and right back wounds were divided into five groups for wound care. The first group was not treated, while the second group was given Bioplacenton ointment, a placenta extract that stimulates tissue formation and heals wounds. The third group was given a gel base without active substance, phytosome gel, and white turmeric extract gel. The fourth group was given the extracted gel, and the fifth group was given the base gel. Each group was sacrificed with a different duration.

This study used healthy albino male Wistar rats weighing 270-300 grams and aged 4-6 weeks as experimental animals (Yanai et al. 2016). Albino male Wistar rats were chosen because of their similar characteristics to humans, good endurance, and ease of food management. This allows research to be conducted more accurately and with less bias (Novita, 2015).

Experimental animals are often used in research because they are easy to control, have a short life cycle, and are relatively affordable. In addition, animals can be selected based on their sensitivity to specific treatments, allowing multi-generation research and production of biological preparations (Ridwan, 2013).

Many studies have been conducted to identify active plant compounds and their effects on wound healing. Animal experiments make assessing compound concentrations, effects, and tissue examinations easier (Ghosh & Gaba, 2013).

Temu putih, which has long been used in traditional Indonesian medicine, contains various active compounds such as curcuminoids, essential oils, polysaccharides, flavonoids, and saponins (Handajani, 2013). This content is thought to be responsible for the various properties of temu putih in overcoming various health problems (Lianah, 2019) (Wati et al., 2018).

Previous research (Gafar & Agustini, 2020) revealed that temu putih is rich in active compounds such as flavonoids and curcuminoids, which provide it with various health benefits, including as an antioxidant and antibacterial. Recent research (Pimrat et al., 2021) found that steaming can increase the curcuminoid content in temu putih. Steamed temu putih extracts, whether or not using 95% ethanol, were effective against several types of bacteria and fungi. In addition, steamed extracts with 95% ethanol are also very effective in inhibiting the production of inflammatory compounds (nitric oxide).

Research results (Kaushik et al., 2021) and (Kg Ileperuma et al., 2022) show that various Curcuma zedoaria preparations have anti-inflammatory activity. However, there were differences in terms of the type of extract used and the evaluation methods applied. Overall, these studies provide preliminary evidence regarding the potential of C. zedoaria as a source of anti-inflammatory compounds.

Temu Putih has shown various pharmacological activities in several studies. (Barus, 2021) reported the burn healing effect of ethanol extract of white temu. (Wulandari & Puspitasari, 2019) The impact of white temu rhizome infuse on the immune system was examined, and an increase in the number of leukocytes and granulocytes was observed. In addition, (Ifmaily et al. 2021) found an anti-inflammatory effect of white temu leaf extract gel. (Desmiaty et al. 2020) It also confirmed the strong antioxidant activity of *C. zedoaria* extract.

The wound-healing process is very complex and is influenced by various factors, one of which is growth factors. This study focuses on essential growth factors such as VEGF, TGF- β 1, FGF, and KGF in wound healing. (Whitney, 2005)

TGF- β 1 is very important in the wound healing process, especially at the stage of new tissue formation to wound completion. This protein stimulates the growth of cells that form granulation tissue and new blood vessels, which will then be replaced by normal skin tissue (Pakyari et al., 2013).

VEGF is an important protein that stimulates the growth of new blood vessels. This protein is crucial in wound healing, where new blood vessels are needed to carry oxygen and nutrients to the injured area. For wounds to heal quickly, the body needs to form new tissue and blood vessels. VEGF is a substance that triggers the growth of new blood vessels so that wounds can get enough oxygen and nutrients for the healing process.

This study evaluated the effectiveness of white turmeric extract phytosome gel in accelerating the healing of open wounds in laboratory mice. The concentration used in this study was 0.5 grams, previously determined through preliminary tests. Gel was chosen as the dosage form because it is more suitable for direct application to the wound area.

Topical medication consists of two main parts: the active ingredient that heals and the base ingredient that transports the active ingredient to the skin. A good base ingredient should be easy to apply, clean, non-irritating, and comfortable to use. The active ingredient should mix well with the base ingredient and be quickly released when applied to the skin (Yanhedri, Yenny SW, 2012).

The gel is a semi-solid, precise, or slightly clear preparation easily absorbed by the skin. Gel-forming materials, such as polymers, give the gel a net-like structure that can accommodate active substances. Gels are often used for direct skin treatment because they are light and non-sticky.

This study evaluated the wound healing process through histopathological analysis, TGF- β 1 levels, and VEGF. The indicators used include the speed of re-epithelialization, granulation tissue thickness, collagen density, skin regeneration, and new blood vessel formation (Perez G et al., 2005). This study measured the wound healing process by observing the thickness of granulation tissue, the number of inflammatory cells, and the extent to which the epithelium covers the wound microscopically. These three factors are assessed using a particular scale and are a common method used in wound research.

1. TGF β 1 Levels and Wound Healing Process

TGF-beta 1 is a key molecule in the repair of damaged tissue. The wound-healing process begins with blood clotting (hemostasis) and is followed by inflammation. In the inflammatory stage, the body sends white blood cells to fight infection and start the repair process. TGF-beta 1 plays a role in attracting white blood cells to the wound area (Finnson et al, 2013).

The results showed a general increase in TGF β 1 levels in all treatment groups compared to the control group. The most significant growth occurred in the extract gel group, especially on day 11. Statistical analysis confirmed a significant difference between the treatment and control groups.

TGF- β 1 is very important in wound healing. This protein activates cells that help build new tissue and reduce inflammation. In addition, TGF- β 1 also stimulates the formation of collagen which strengthens the wound. Regulating TGF- β 1 levels can speed up the healing process, especially under challenging wounds (Chakraborty D et al, 2020).

2. VEGF Levels and Wound Healing Process

VEGF, a growth protein, plays a central role in wound healing. By stimulating the formation of new blood vessels, VEGF ensures an adequate supply of nutrients and oxygen to cells that are repairing damaged tissue. This process is crucial, especially during the growth stage of new tissue.

VEGF works by stimulating the growth of new blood vessels, thereby increasing blood flow to the injured area. This increased blood flow brings oxygen and nutrients to support tissue repair. In addition, VEGF also helps cells that play a role in healing, such as fibroblasts and keratinocytes, to function more efficiently.

Based on the study, all treatment groups experienced an increase in VEGF levels from day 3 to day 7. However, the group given white turmeric extract phytosome gel and white turmeric extract gel showed the most significant increase in VEGF levels. The statistical test results confirmed that the difference in the increase in VEGF levels between the two treatment groups with the control group and natural healing was significant. These findings indicate that white turmeric extract, both in the form of phytosome gel and regular gel, has a better effect in stimulating the growth of new blood vessels compared to other treatment methods. When an acute wound occurs, the body automatically increases the production of VEGF to repair damaged tissue. VEGF functions to form new blood vessels so that the wound gets enough oxygen. VEGF is an essential factor in wound healing, especially in the phase of new tissue formation (Zhao, X., et al, 2021). By increasing blood vessel production, VEGF accelerates the healing process and reduces the risk of complications in acute wounds. Therapy that increases VEGF levels, either topically or by injection, can be an effective solution to overcome the problem of slow wound healing (Luo, G. et al., 2022).

9. Effect of White Turmeric Extract Phytosome Gel on Wound Healing

Based on hereditary experience, white turmeric (*Curcuma zedoaria* Rosc.) has been widely used by the Indonesian people as a herbal medicine (Handajani, 2013) (Lianah, 2019). This plant is believed to be effective in treating various health complaints, including digestive disorders, wounds, and ulcers. Scientific research shows that white turmeric contains multiple bioactive compounds, such as curcuminoids, essential oils, and flavonoids, which contribute to its pharmacological properties (Wati et al., 2018). (Gafar & Agustini, 2020) Other researchers have identified various bioactive compounds in white turmeric that contribute to various pharmacological activities. (Pimrat et al., 2021) Found that extraction using 95% ethanol on steamed rhizomes produced the highest curcuminoid content. In addition, research (Ifmaily et al., 2021) and (Desmiaty et al., 2020) successfully developed white turmeric-based gel and emulgel formulations with good anti-inflammatory and antioxidant activities.

Curcuma zedoaria, or white turmeric, contains various bioactive components with broad pharmacological activities, including the ability to accelerate wound healing. The mechanism of action involves the anti-inflammatory, antibacterial, and antimicrobial properties of compounds such as curcuminoids and flavonoids, which control inflammation and infection and stimulate new tissue growth.

Curcumin, flavonoids, terpenoids, and essential oils are the main components in white turmeric that play an important role in the wound healing process. Curcumin, for example, can reduce inflammation and fight infection. Meanwhile, flavonoids and terpenoids also reduce inflammation and increase cell regeneration. Essential oils function as natural antiseptics that protect wounds from infection.

White turmeric, especially its curcuminoid content, has been shown to be effective in accelerating wound healing in mice. This is due to its ability to stimulate the growth of new skin cells, increase collagen production, and reduce inflammation (Bhandari P. et al., 2020). Research shows that active compounds in white turmeric, such as curcuminoids and flavonoids, have an effect on TGF- β 1 and VEGF levels, which play an important role in the wound healing process. White turmeric, especially its curcuminoid content, is very effective in accelerating wound healing. This compound works by

reducing cell damage caused by free radicals, reducing inflammation, and stimulating cell growth and the formation of new tissue. Its mechanism of action involves activating specific genes that play a role in forming collagen and blood vessels (Kumar, S., et al, 2019). Phytosomes, an innovation in drug and supplement formulation, combines active plant compounds with phospholipids to increase drug absorption and effectiveness (Haruni et al., 2019). The main advantage of phytosomes is their ability to bind plant compounds specifically to the hydrophilic part of phospholipids, unlike other delivery systems that only trap these compounds (Putri Febrianti et al., 2023). According to Singh R. et al (2021), Phytosome gel, a combination of active plant compounds with phospholipids, effectively accelerates wound healing. Research shows that this gel is able to reduce inflammation, increase the formation of new tissue, and accelerate skin regeneration. This is possible because phytosomes increase the penetration ability of active ingredients into the skin, so the therapeutic effect is more optimal (Raza, K., et al, 2022).

The study showed the superiority of phytosome gel and extract gel in wound healing compared to the control and natural healing groups. Analysis of wound diameter on day 11 indicated a faster healing rate in the phytosome gel group. Friedman's non-parametric statistical test confirmed a significant difference between treatment groups ($p < 0.05$), supporting the hypothesis that this gel formulation has a better therapeutic effect. These findings are consistent with existing literature on the potential of white turmeric extract in stimulating fibroblast proliferation and granulation tissue formation.

The results of this study highlight an interesting response from the phytosome gel group. Although initially showing a decrease in TGF- β 1 and VEGF levels, this group then experienced a substantial increase in the subsequent treatment period. This finding indicates a dynamic effect of the phytosome gel on growth factor regulation.

Based on statistical tests, the white turmeric extract phytosome gel significantly increased VEGF levels compared to the control group and the regular white turmeric extract gel. This indicates that the phytosome formulation is able to increase the effectiveness of white turmeric extract in improving the growth of new blood vessels.

Based on tissue observations on the 11th day after treatment, all groups showed the same and optimal level of granulation tissue formation. The statistical test results confirmed no significant difference between these groups in terms of granulation tissue formation.

Regarding inflammatory cells, the number of inflammatory cells that were slightly increased from day 3 to day 11 in all groups. In contrast, the number of inflammatory cells that were moderate in number continued to decrease during the same period. No large inflammatory cells were found in all groups. Statistical analysis also showed no significant difference between the treatment groups regarding the number of inflammatory cells.

Kruskal-Wallis statistical analysis found no significant difference in the rate of wound healing between the experimental groups at any time point observed. At the beginning of the observation (day 3), most wounds were still in the early healing stage. Towards the middle of the observation period (day 7), most wounds showed significant progress but had not completely healed. Most of the scars had healed entirely at the end of the observation (day 11). This finding is in line with previous research. According to research by Fazal, A., et al. (2021), white turmeric extract positively affects the wound healing process, which may be related to its curcumin and flavonoid content. This study has two significant limitations. First, the absence of baseline data on TGF- β 1 levels makes it difficult to track changes in levels. Second, using different mice at each measurement time can affect the study results due to individual variations.

CONCLUSION

Preparing phytosome gel from white turmeric extract (*Curcuma zedoaria* Rosc) has increased acute wound closure, healing, tissue epithelialization, TGF- β 1 levels, and VEGF levels. The gel showed faster wound closure diameter and granulation tissue thinning than the control group. The gel also

accelerated tissue epithelialization and increased TGF- β 1 levels from day 3 to day 11. Furthermore, the gel showed higher VEGF levels compared to the positive control group.

REFERENCE

- Alexiadou, K., & Doupis, J. (2012). Management of diabetic foot ulcers. *DiabetesTherapy*, 3(1), 1–15. <https://doi.org/10.1007/s13300-012-0004-9>
- Barrientos, S., Stojadinovic, O., Golinko, M. S., Brem, H., & Tomic-Canic, M. (2008). Growth factors and cytokines in wound healing. *Wound Repair and Regeneration*, 16(5), 585–601. <https://doi.org/10.1111/j.1524-475X.2008.00410.x>
- Barus, B. R. (2021). Perbandingan Konsentrasi Ekstrak Etanol Daun Bau-Bau (*Chromolaena odorata* (L.) King & H.E. Robins) Dan Ekstrak Etanol Temu Putih (*Curcuma zedoaria* (Berog) Rosc) terhadap Penyembuhan Luka Bakar pada Kelinci. *Jurnal Penelitian Farmasi & Herbal*, 3(2), 14–20. <https://doi.org/10.36656/jpfh.v3i2.654>
- Bruhn-Olszewska, B., Korzon-Burakowska, A., Gabig-Cimińska, M., Olszewski, P., Wegrzyn, A., & Jakóbkiewicz-Banecka, J. (2012). Molecular factors involved in the development of diabetic foot syndrome. *Acta Biochimica Polonica*, 59(4), 507–513. <https://doi.org/10.18388/abp.2012.2085>
- Busman, Edrizal, & Wirahmi, S. D. (2019). Daya Hambat Ekstrak Rimpang Temu Putih (*Curcuma zedoaria*) Terhadap *Streptococcus Mutans* dan *Staphylococcus aureus*. *Jurnal Penelitian Dan Kajian Ilmiah Menara Ilmu*, 8(6), 19–28.
- Chakraborty, D., et al. (2020). "TGF- β 1 in Wound Healing: Mechanistic Insights and Novel Therapeutic Approaches". *Frontiers in Physiology*, 11, 578236. [DOI: 10.3389/fphys.2020.578236]
- Clinton, A., & Carter, T. (2015). Chronic wound biofilms: Pathogenesis and potential therapies. *Lab Medicine*, 46(4), 277–284. <https://doi.org/10.1309/LMBNSWKUI4JPN7SO>
- Dahlman, D., Håkansson, A., Kral, A. H., Wenger, L., Ball, E. L., & Novak, S. P. (2017). Behavioral characteristics and injection practices associated with skin and soft tissue infections among people who inject drugs: A community-based observational study. *Substance Abuse*, 38(1), 105–112. <https://doi.org/10.1080/0897077.2016.1263592>
- Desmiaty, Y., Winarti, W., Lindawati, & Fahleni, F. (2020). Formulasi *Curcuma zedoaria* sebagai Emulgel Antioksidan (Formulation of *Curcuma zedoaria* asan Antioxidant Emulgel). *Jurnal Ilmu Kefarmasian Indonesia*, 18(1), 34–40. <https://doi.org/https://doi.org/10.35814/jifi.v17i2.755>
- Dewi, A. U., & Wicaksono, I. A. (2020). Review Artikel: Tanaman Herbal yang Memiliki Aktivitas Penyembuhan Luka. *Farmaka*, 18(2), 191–207.
- Elmitra. (2017). *Dasar-Dasar Farmasetika dan Sediaan Semi Solid*. Deepublish.
- Falanga, V. (2005). Wound healing and its impairment in the diabetic foot. *Lancet*, 366(9498), 1736–1743. [https://doi.org/10.1016/S0140-6736\(05\)67700-8](https://doi.org/10.1016/S0140-6736(05)67700-8)
- Fazal, A., et al. (2021). "Wound Healing Efficacy of *Curcuma zedoaria* Root Extract in Animal Models." *Journal of Traditional and Complementary Medicine*, 11(2), 114–120. [DOI: 10.1016/j.jtcme.2021.02.004]
- Finnson, K. W., McLean, S., Di Guglielmo, G. M., & Philip, A. (2013). Dynamics of Transforming Growth Factor Beta Signaling in Wound Healing and Scarring. *Advances in Wound Care*, 2(5), 195–214. <https://doi.org/10.1089/wound.2013.0429>
- Gafar, P. A., & Agustini, S. (2020). Antioxidant Activity of Blended Robusta Coffee (*Coffea canephora* L.) with the White Turmeric (*Curcuma zedoaria* (Berg.) Roscoe) and Wild Ginger (*Curcuma xanthorrhiza*, Roxb.). *IOP Conference Series: Materials Science and Engineering*, 742(1). <https://doi.org/10.1088/1757-899X/742/1/012018>
- Guo, S.; L. A, D. (2010). Factors affecting wound healing. *Journal of Dental Research*, 89(3).
- Handajani, J. (2013). Minyak Atsiri Temu Putih (*Curcuma Zedoaria* Rosc., Zingiberaceae) Menurunkan Ekspresi CD4+ Pada Gingiva Terpapar *A. Actinomyces* *comitans*. *Majalah Kedokteran Gigi Indonesia*, 20(1), 9. <https://doi.org/10.22146/majkedgiind.8194>

- Idayanti, T., Umami, S. F., Anggraeni, W., & Virgia, V. (2022). *Asuhan neonatus, bayi dan balita untuk mahasiswa kebidanan*. Rizmedia Pustaka Indonesia.
- Ifmaily, Islamiyah, S. B., & Fitriani, P. R. (2021). Efek Gel Daun Temu Putih (*Curcuma zedoaria* (Christm.) Roscoe) Sebagai Antiinflamasi Dengan Metoda Induksi Karagen Dan Kantong Granuloma Pada Mencit Putih Jantan. *Jurnal Inovasi Penelitian*, 1(3), 1–4.
- Kalluri, R., & Zeisberg, M. (2020). Fibroblast in Wound Healing and Fibrosis". *Nature Reviews Medicine*.
- Kartika, R. W., Bedah, B., Paru, J., & Luka, A. P. (2015). Perawatan Luka Kronis dengan Modern Dressing. *Perawatan Luka Kronis Dengan Modern Dressing*, 42(7), 546–550.
- Kaushik, M., Kadian, J. P., & Chauhan, B. (2021). A prospective screening of anti-inflammatory activity of mono herbal formulations of curcuma zedoria. *International Journal of Pharmaceutical Research*, 13(01). <https://doi.org/10.31838/ijpr/2021.13.01.473>
- Kg, I., Ru, S., Hpd, D. S., Samanmali, B. L. C., Wjabn, J., Lanka, S., Farmasi, I., Ilmu, F., Sekutu, K., Jayewardene, U. S., & Lanka, S. (2022). *Evaluasi dari in vitro aktivitas anti-inflamasi dari fraksi yang berbeda dari ekstrak air Curcuma zedoaria Rimpang Roscoe dan formulasi krim dengan potensi anti-inflamasi*. 12(1), 20–32.
- Lazuardi, M. (2020). *Bagian Khusus Ilmu Farmasi Veteriner Ed 1*. Airlangga University Press.
- Li, J., Chen, J., & Kirsner, R. (2007). Pathophysiology of acute wound healing. *Clinics in Dermatology*, 25(1), 9–18. <https://doi.org/10.1016/j.clindermatol.2006.09.007>
- Lianah. (2019). *Biodiversitas Zingiberaceae; Mijen Kota Semarang*. Deepublish.
- Novita, R., 2015. Pemilihan Hewan Coba pada Penelitian Pengembangan Vaksin Tuberculosis. *Biotek Medisiana Indonesia*, 4(2), pp. 15–24.
- Pakyari, M., Farrokhi, A., Maharlooee, M. K., & Ghahary, A. (2013). Critical Role of Transforming Growth Factor Beta in Different Phases of Wound Healing. *Advances in Wound Care*, 2(5), 215–224. <https://doi.org/10.1089/wound.2012.0406>
- Paliwal, R. Et al (2021). Nanocarriers for the delivery of Drugs to Target Tissues".
- Pastar, I., Stojadinovic, O., Yin, N. C., Ramirez, H., Nusbaum, A. G., Sawaya, A., Patel, S. B., Khalid, L., Isseroff, R. R., & Tomic-Canic, M. (2014). Epithelialization in Wound Healing: A Comprehensive Review. *Advances in Wound Care*, 3(7), 445–464. <https://doi.org/10.1089/wound.2013.0473>
- Perez G, R.M., Vargas S,R. & Ortiz H, Y.D., 2005. Wound Healing properties of *Hylocereus undatus* on diabetic rats. *Phytotherapy research : PTR*, 19 (8), pp. 665–8. Available at: <http://www.ncbi.nlm.nih.gov/pubmed/16177967>.
- Perini, J.A. et al., 2015. Topical application of Acheflan on rat skin injury accelerates wound healing : a histopathological, immunohistochemical and biochemical study. *BMC Complementary and Alternative Medicine*, pp. 1–8. Available at: <http://dx.doi.org/10.1186/s12906-015-0745-x>.
- Penn, ack W ; Adriaan O Grobbelaar, K. J. R. (2012). The role of the TGF- β family in wound healing, burns and scarring: a review. *International Journal Of Burns and Trauma*, 1(2).
- Pimrat, N., Panthong, S., & Itharat, A. (2021). *Effect of steaming process on chemical content and biological activity of curcuma zedoaria extract*. 21(1), 45–54. <https://asianmedjam.com/index.php/amjam/article/view/237/230>
- Prabakti, Y. (2005). Perbedaan Jumlah Fibroblas Di Sekitar Luka Insisi Pada Tikus Yang Diberi Infiltrasi Penghilang Nyeri Levobupivakain Dan Yang Tidak Diberi Levobupivakain. *Tesis*, 2(3), 20–22.
- Prasetyono, T. O. H. (2009). General concept of wound healing, revisited. *Medical Journal of Indonesia*, 18(3), 208–216. <https://doi.org/10.13181/mji.v18i3.364>
- Qin, Z., et al (2021). *VEGF and Its Rules in Wound Healing*. *Journal of Cellular Physiology*.
- Raza, K., et al. (2022). "Fitosomal Gel for Wound Healing: A Novel Approach to Deliver Phytochemicals". *Biotechnology Reports*, 33, e00723. [DOI: 10.1016/j.btre.2022.e00723]
- Ridwan, E., 2013. Etika Pemanfaatan Hewan Percobaan dalam Penelitian Kesehatan. *Indon Med Assoc*, 63(3), pp. 112–116.
- Risal Wintoko, A. D. N. Y. (2020). 2893-3593-1-Pb. *Jurnal Kesehatan Universitas Lampung*, 4, 183–189.

- Ruiz-Ortega, M., Rodríguez-Vita, J., Sanchez-Lopez, E., Carvajal, G., & Egidio, J. (2007). TGF- β signaling in vascular fibrosis. *Cardiovascular Research*, 74(2), 196–206. <https://doi.org/10.1016/j.cardiores.2007.02.008>
- Sari, W. A. I. M. (2022). Gambaran Tingkat Pengetahuan Ibu tentang Pertolongan Pertama Luka Bakar Anak Usia Toddler. *ULIL ALBAB : Jurnal Ilmiah Multidisiplin*, 1(Vol. 1 No. 12: November 2022), 4451–4459. <https://ulilalbabinstitute.com/index.php/JIM/article/view/1115/885>
- Singh, R., et al. (2021). "Fitosomal Formulation of Medicinal Plants for Wound Healing Applications: Recent Advances". *Advanced Drug Delivery Reviews*, 173, 134-149. [DOI: 10.1016/j.addr.2021.01.007]
- Shibuya, M. (2021). *Vascular Endothelial Growth Factor (VEGF) and Its Receptor(s) in Angiogenesis*". Cytokines & Growth Factor Reviews.
- Suranto, A. (2004). *Khasiat & Manfaat Madu Herbal*. AgroMedia Pustaka.
- Tahergorabi, Z. M. K. (2012). *A Review on Angiogenesis and Its Assays*. 6(15).
- Velnar, T., Bailey, T., & Smrkolj, V. (2009). The wound healing process: An overview of the cellular and molecular mechanisms. *Journal of International Medical Research*, 37(5), 1528–1542. <https://doi.org/10.1177/147323000903700531>
- Wati, I., Ramadanti, M., & Pratiwi, H. (2018). Pengaruh Konentrasi Pelarut, Dan Nisbah Bahan Baku Dengan Pelarut Terhadap Ekstraksi Kunyit Putih (*Curcuma zedoria*). *Itenas Repository*, 20–26.
- Wulandari, R., & Puspitasari, P. (2019). Roscoe) Terhadap Jumlah Leukosit Dan Differential Counting (Diffcount) Pada Kesembuhan Luka Laparatomi. *Medical (Journal of Medical Laboratory Science Technology)*, 2(1), 22–27. <https://doi.org/10.21070/medicra.v2i1.1689>
- Yanai, J. Et.al., 2016. Acceleration of wound healing by topical application of honey. An animal model acceleration of wound healing by topical application of Honey. *The American Journal of Surgery*, 9610, pp. 374-376.
- Young, A. & McNaught, C. (2011). The physiology of wound healing. *Surgery (Oxford)*, 10.
- Young, A. & McNaught, C_E., 2011. The physiology of wound healing. *Surgery (Oxford)*, 29(10), pp.475-479.
- Zhao, X., et al. (2021). "The Role of VEGF in Wound Healing and Its Potential in Therapy". *Journal of Translational Medicine*, 19(1), 249. [DOI: 10.1186/s12967-021-02829-1]
- Zoya Tahergorabi, M.K. 2012. A review on Angiogenesis and Its Assays. *Iranian Journal of Basic Medical Sciences*. 15(6), pp. 1110-1126.