

RESEARCH ARTICLE

Management of Bacterial Chronic Osteomyelitis of the Shaft of Lower Limb Bones by Surgical Debridement with Bone Sliding in a Single Stage

Haitham Al-Ahmer¹, Fouad Al-Daoud², Gohar Mushtaq^{3*}, Khaled Emar⁴

¹Department of Orthopedics Surgery, Idlib University, Idlib, Syria

²Department of Microbiology, Idlib University, Idlib, Syria

³Center for Scientific Research, Idlib University, Idlib, Syria

⁴Department of Orthopedic Surgery, Ain Shams University, Cairo, Egypt

ARTICLE INFO

Received: Mar 17, 2024

Accepted: May 12, 2024

Keywords

Chronic osteomyelitis

Surgical debridement

The shaft of the lower limb

Single stage

Bone sliding

*Corresponding Author:

dr.gohar_mushtaq@

idlib-university.com

ABSTRACT

During times of war injuries and irrational fracture management, cases of chronic bacterial osteomyelitis are highly likely to develop. This study aims to address chronic bacterial osteomyelitis efficiently with minimal time and fewer procedures. Our study focused on 31 patients over two and a half years. Clinical history, clinical examination, radiological investigations, and laboratory tests established the diagnosis with precision and certainty. Surgery was performed with meticulous, wide surgical debridement. External fixation was employed for bone and soft tissue reconstruction; in specific cases, internal fixation was used along with external fixation and treatment with antibiotics against the isolated pathogen. Of the thirty-one patients diagnosed with chronic bacterial osteomyelitis, nineteen (61.3%) had it in the femur, while the remaining twelve cases (38.7%) occurred in the tibia. Wide surgical debridement with tissue sampling was performed in all cases. External fixation alone was employed in 11 femur cases (57.9%) and 8 tibia cases (66.7%), whereas a combination of internal fixation and external fixation was utilized in 8 femur cases (42.1%) and 4 tibia cases (33.3%). In the femur patient group, bone results assessed using the ASAMI Scoring System were excellent in 10 patients (52.7%), good in 5 patients (26.3%), fair in one patient (5.2%), and poor in 3 patients (15.8%). Conversely, among the tibia patients, bone results were excellent in 10 patients (83.3%) and good in 2 patients (16.7%), with no cases falling into the fair or poor categories. External fixation plays a crucial role in bone and soft tissue reconstruction at the site of bone defects. In contrast, combined internal fixation may be warranted in cases with extensive bone loss following surgical debridement, thus aiming to reduce complications associated with external fixation alone.

INTRODUCTION

While growing global conflicts and heightened warfare, there has been a notable increase in war-related injuries, particularly severe injuries that involve complex contaminated fractures (Nawfal Dagher et al., 2020). The occurrence of chronic bacterial osteomyelitis is on the rise, primarily due to the proliferation of predisposing conditions, especially war-related injuries, which have significantly increased over the past decade and continue to escalate rapidly (Garcia del Pozo et al., 2018). Additionally, the prevalence of diabetes, smoking, vascular diseases in the extremities, severe and contaminated crush injuries, and open fractures contribute to this increasing trend (Hannan and Attinger, 2009; Ye et al., 2021). Insufficient and inadequately planned treatments are commonly attributed as the leading cause of chronic bacterial osteomyelitis (Subramanyam et al., 2023), particularly in third-world countries where there is often a shortage of medical expertise and essential treatment equipment (Taleb et al., 2015). Random and nontargeted use of antibiotics further compounds the problem (Jerzy and Francis, 2018). Indeed, pyogenic bacteria are the primary causative agents of osteomyelitis, and they can result from a localized infection or the spread of bacteria through the bloodstream (Saye, 2007; Wang et al., 2022). This can result in infection affecting different parts of the bone, including the cortex, cancellous bone, and bone marrow (Azar et al., 2022).

Osteomyelitis is generally classified as acute, subacute, or chronic based on pathological tissue studies, in addition to the duration of the infection (Carek et al., 2001). Acute osteomyelitis is associated with inflammatory bone changes caused by pathogenic bacteria. Symptoms typically appear within two weeks after the infection. Chronic osteomyelitis is characterized by bone necrosis, and symptoms may not manifest until at least six weeks after the onset of the infection (Hatzenbuehler and Pulling, 2011; Hadier et al., 2023; Taki et al., 2016), often presenting in a milder form (Hotchen et al., 2017). Osteomyelitis often develops from a direct bone injury that is not thoroughly treated or from adjacent foci. It is considered a common complication of open fractures and can also occur due to other reasons,

such as diabetic foot infections. This is often due to highly virulent and antibiotic-resistant bacteria (Giwanatara and Hendrawan, 2021; Jam et al., 2011; Pande, 2015). Chronic bacterial osteomyelitis is typically a secondary condition resulting from open fractures, bacteremia, or infection from adjacent soft tissues. The incidence of infection within three months after an open fracture can be as high as 27%. Hematogenous osteomyelitis, which originates from the bloodstream, is less common in adults than in children and usually involves the vertebrae but can also occur in long bones, the pelvis, or the clavicle (Aydingoz, 2023; Aderibigbe et al., 2024; Hatzenbuehler and Pulling, 2011). Clinical symptoms of bacterial chronic osteomyelitis are often nonspecific and hard to identify. These may include chronic pain, persistent sinus tracts or wound drainage, delayed wound healing, local tenderness, and, occasionally, fever (Putri et al., 2016; Zimmerli, 2021). Successful treatment relies on meticulous and extensive surgical debridement, bone and soft tissue reconstruction, and targeted antibiotic therapy (Armstrong and Rush, 1983).

INFORMATION AND CRITERIA FOR PATIENTS

Our study was conducted between January 2021 and July 2023 and was carried out in northwest Syria. It included 31 patients diagnosed with chronic osteomyelitis. The diagnosis relied on comprehensive diagnostic procedures, including detailed clinical history, identification of risk factors, meticulous clinical examination, laboratory results (CBC, CRP, and ESR) (York et al., 2014), diagnostic imaging such as plain radiography, CT scans, MRIs, and bone scans (if available), bacterial cultures, and tissue biopsy (Hotchen et al., 2017; Steinhausen et al., 2016). Our patients were classified as 3A and 4A/B based on the classification (Marais et al., 2015; Townsend and Koç, 2023). The Lautenbach classification is also important for assessing chronic osteomyelitis's severity and laboratory-directed evaluation (Marais et al., 2015).

The patients were divided into two groups. The first group comprised individuals diagnosed with chronic osteomyelitis in the thigh, totaling 19 patients (61.3%). The second group included patients with chronic osteomyelitis in the leg, with 12 patients

(38.7%). The categorization of cases was determined by the location of the infection, specifically whether it occurred in the left or right limb. In the group with chronic osteomyelitis in the thigh, there were 15 patients with the infection on the left side (79%) and 4 patients on the right side (21%). In the group with chronic osteomyelitis in the leg, there were 8 patients with infection on the left side (66.7%) and 4 patients with osteomyelitis on the right side (33.3%). The total percentage for both groups on the left side was 74.2% (23 patients), and on the right side, it was 25.8% (8 patients).

The age range of the patients varied from 14 to 72 years, with a mean age of 36.7 years, indicating that most of the patients were young adults. This is attributed to the fact that most cases result from bone loss due to gunshot wounds or shrapnel, and young adults are more exposed to such injuries (Tabakan et al., 2021). Among the patients, 29 were males (93.5%), and 2 were females (6.5%), indicating a higher prevalence of cases among males in our study, likely due to war-related injuries and traffic accidents, which are more common among males due to their higher level of activity in these events.

The numbers of cases categorized by the type of initial injury that ultimately led to chronic bacterial osteomyelitis in the thigh were as follows: 9 patients due to war-related injuries, 9 patients due to traffic accidents, and one patient due to a fall. The numbers of cases categorized by the type of initial injury that ultimately led to chronic bacterial osteomyelitis in the leg were as follows: 8 patients due to war-related injuries, 3 patients due to traffic accidents, and one patient due to a fall. The total number of patients in both groups was 17 due to war-related injuries (54.9%), 12 due to traffic accidents (38.7%), and 2 due to falls (6.4%). The categorization of fractures in the initial injuries was determined by whether they were closed or open fractures, following the Gustilo and Anderson classification (Messori et al., 2017). Cases of chronic bacterial osteomyelitis were distributed in the thigh to 8 patients due to closed fractures and 11 patients due to open fractures (G (1, 2, 3A, and 3B)). Additionally, there were 2 patients with bacterial chronic osteomyelitis in the leg due to closed fractures and 10 patients due to open fractures (G (1, 2, 3A, and 3B)). There were 31 patients, with 10 (32.2%)

having closed fractures and 21 (67.8%) having open fractures.

Among the patients were 18 smokers, accounting for 58%, and 13 nonsmokers, accounting for 42%. Thus, more than half of the patients were smokers. Additionally, there were 4 patients with diabetes (12.9%) and 27 patients without diabetes (87.1%). The number of patients with chronic osteomyelitis in the thigh and leg who did not have nonunion at the fracture site was 29 (93.5%). In comparison, surgical intervention was performed to treat chronic osteomyelitis in two cases of previous union (6.5%). The first case (union bacterial chronic osteomyelitis) involved a patient with chronic osteomyelitis in the thigh who underwent 11 surgical procedures for debridement of the infection without success. The second case involved a patient with chronic osteomyelitis in the leg who underwent nine surgical procedures to remove the infection without success.

Preoperative preparation

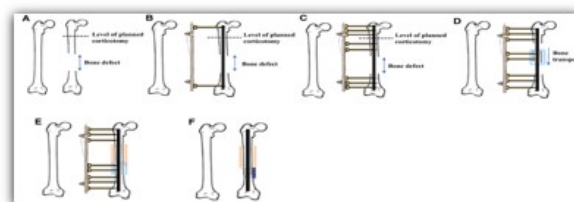
Patients were admitted to the hospital and underwent a preoperative assessment, including inflammatory markers (CBC, CRP, and ESR), as well as consultation with an anesthesiologist regarding the surgical procedure. Blood group, INR, PT tests, and blood products were prepared. Three days or a week before surgery, all antibiotics previously taken by the patient were discontinued, and on the day of surgery, the old external fixator was removed, and a serum or pus sample was taken from the fistula site of chronic bacterial osteomyelitis. The patients were instructed to shower on the morning of the surgical procedure and to fast completely for 8 hours before the surgery. Full hair removal was performed on the affected limb as needed. The patients were dressed in special surgical attire. A serum or purulent sample was taken from the abscess if possible. The surgical table was prepared with a complete surgical setup, including general and specialized orthopedic surgical instruments. Depending on the anesthesia consultation, the patients were anesthetized either under general anesthesia or regionally.

Surgical procedures

The patients would lay on their backs on a specialized operating table (supin). The surgical area was thoroughly sterilized with a three-fold iodine solution, and sterile drapes were applied. A surgical incision

was made at the site of the previous surgeries and scars. The area was carefully dissected to reach the site of the bacterial infection. If internal metallic implants were present, they were removed. A precise and wide surgical debridement of the infected area, including removing bone fragments and bone cavities until clean, bloodied, noninfected bone and soft tissues were obtained (cutting a completely infected bone segment). During surgery, three tissue samples were collected from different areas within the surgical field. These tissue samples included bone fragments, sequestrum, or soft tissue that appeared necrotic. These tissue samples were used for both aerobic and anaerobic bacterial cultures to identify the type of bacteria present and their gram-positive or gram-negative nature. During the surgical procedure,

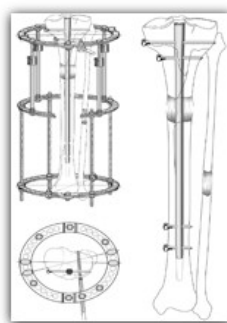
bone cuts were performed either above or below the infected bone, or in some cases, bone cuts were made both above and below the infected bone after debridement. In cases of the absence of serum or pus drainage or when the resulting bone defect after meticulous surgical debridement was greater than 2 cm, internal fixation with an intramedullary nail (interlocking) was performed following the prior surgical debridement. The intramedullary nail was locked at both the proximal and distal ends, and a single-sided sliding external fixator or an Ilizarov apparatus was applied to the resulting three or four bone segments. The technique involved placing the pins at a distance from the intramedullary nail to prevent infection from the external environment to the fixation site. (Fig. 1).



A



B



C

Figure 1: (A) Method of inserting pins of the external fixator at a level different from the level of the interlocking nail in the femur [Figure Ref: (Lu et al., 2022)] and in the tibia (B) (C) [Figure Ref:(Burghardt et al., 2016)]

In cases where serum or pus drainage was positive or when the resulting bone defect, after a meticulously precise surgical debridement, was less than or equal to 2 cm, a single-sided sliding external fixator or an Ilizarov apparatus was applied to the resulting three or four bone segments without internal fixation. This

was followed by the placement of a suction drain (Redovac at the surgical site) and a meticulous closure of the wound, showcasing the precision of our surgical procedures.

Our study, which involved significant surgical procedures on 31 patients, 19 of whom suffered from

chronic osteomyelitis of the femur and 12 of whom suffered from chronic osteomyelitis of the tibia, is a testament to the importance of our findings. Among them, 29 were male and 2 were female, with a mean age of approximately 36.7 years. Ten patients had experienced a closed fracture at the initial injury, and 21 patients had experienced an open fracture. The mean number of previous surgeries performed under the same conditions for patients with chronic osteomyelitis of the femur was 4.89 surgeries, while for patients in the tibia, it was 6.66 surgeries. The mean bone defect resulting at the end of surgery for chronic osteomyelitis of the femur was 4.47 cm, while the mean bone defect resulting at the end of surgery for chronic osteomyelitis of the tibia was 4.37 cm. External fixation devices (Ilizarov or a single-sided sliding external fixator) were used in 11 patients with the femur and in 8 patients with the tibia in cases where serum or purulent cultures were positive or in cases where the bone defect after precise surgery was less than or equal to 2 cm. An interlocking nail was used in combination with external fixation devices in 8 patients of the femur and 4 patients of the tibia in cases where serum or purulent cultures were negative or where the bone defect after precise surgery exceeded 2 cm. The number of patients with chronic osteomyelitis of the thigh who had limb shortening before surgery was 14 out of 19 cases (73.7%). Meanwhile, the number of patients with limb shortening before surgery was 3 out of 12 (25%).

Postoperative treatment

Upon admission to the ward, the patient is provided with comprehensive pain management and prophylactic anticoagulation. Blood transfusions are administered as needed. Neurovascular monitoring

is conducted, and broad-spectrum intravenous antibiotics are administered, particularly targeting gram-positive and gram-negative bacteria, including MRSA. This regimen continues until the results of bacterial cultures and sensitivities become available. A dressing change is performed 24 hours after surgery, and the patient is then discharged home with detailed instructions for wound care, specific antibiotics, and oral antibiotics for 6 weeks or until ESR and CRP values return to normal (Lipsky et al., 2012; Rao et al., 2011), ensuring a thorough and effective postoperative treatment.

Between five days and one week after the surgery, a follow-up X-ray is performed for monitoring, along with laboratory tests (inflammatory markers: ESR, CRP, CBC). The process of bone distraction begins by adjusting the bone fragment incrementally, moving toward the bone defect in increments of 0.5 mm twice daily.

Following the surgery, the patient's progress was closely monitored every 6 weeks with X-rays and laboratory tests (ESR, CRP, CBC). The process of bone distraction began by adjusting the bone fragment incrementally, moving toward the bone defect in increments of 0.5 mm twice daily. This continued until the sliding bone fragment filled the space of the bone defect. The rate of bone distraction was adjusted based on the results of radiological monitoring during the patient's clinic visits. Partial weight-bearing was permitted for the patient, along with extension and flexion exercises of the lower limb joints, starting one week after the surgery (Rozbruch et al., 2015). The external fixation was removed once the desired bone gap was achieved and evidence of good bone bridging was visible.

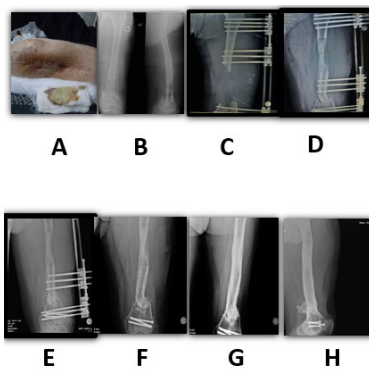


Figure 2: Patient 32-year-old male, war injury

Figure 2 shows a patient 32-year-old male, war injury. (A) A left thigh with purulent drainage from a fistula. (B) (X-ray). Non-union of fracture of lower left femur with bacterial osteomyelitis chronic. (C) Immediately

after surgery, management with a single-sided sliding external fixator. (D) After 6 months. (E) After 8 months. (F) After 12 months. (G) AP view after 18 months. (H) Lateral view after 18 months.

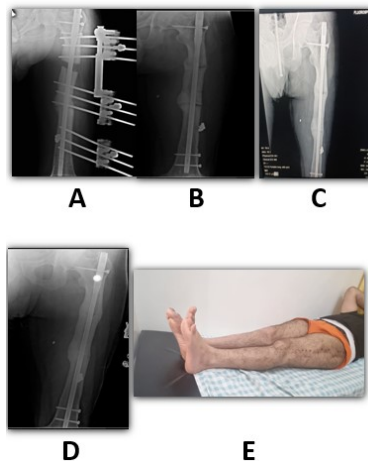


Figure 3: Patient 26-year-old male, traffic accident

Figure 3 shows traffic accident of a 26-year-old male patient. (A) (X-ray) at the end of the sliding stage of the bone segment 8 weeks after surgery for reconstruction to treat bacterial osteomyelitis in the middle part of the left femur by combination with an

interlocking nail and a single-sided sliding external fixator. (B) X-ray one month after removing the external fixator. (C) Eight months after surgery. (D), (E) 18 months after surgery.

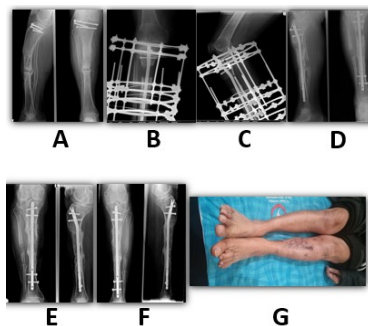


Figure 4: Patient 68-year-old male, traffic accident

Figure 4 displays traffic accident of a 68-year-old male patient. (A) Bacterial nonunion fracture of the left tibia shaft. (B,C) AP and Lateral view. At the end of the sliding stage of the bone segment, 3 months after surgery for reconstruction to treat bacterial nonunion fracture of the left tibia shaft by combination with an interlocking nail and an Ilizarov apparatus. (D) X-ray 4 months after removing an Ilizarov apparatus. (E) 8 months after surgery. (F,G) 14 months after surgery.

Outcome evaluation

Patients were evaluated functionally and in terms of bone assessment, adhering to the criteria established by Aktuglu et al. (2019) and Paley et al. (1989). The bone assessment encompasses four criteria: bone union, infection, deformity, and limb length discrepancy. Functional assessment involves five criteria: obvious limping, adjacent joint contracture, soft tissue atrophy, pain, and the inability to return

to daily life. The outcomes in bone and functional aspects are categorized into four grades: excellent, good, fair, and poor. The final results are clinically and radiologically evaluated and objectively assessed using the ASAMI scoring system (Singh et al., 2019).

RESULTS

After the surgery, following meticulous surgical debridement and radiological evaluation, the mean bone defect for patients with chronic osteomyelitis in the femur was 4.47 cm (ranging from 2 cm to 10 cm). In contrast, for patients with osteomyelitis in the tibia, the mean bone defect was 4.37 cm (ranging from 2 cm to 8 cm). The overall mean bone defect for both groups combined was 4.43 cm.

During the surgical intervention, a tissue sample was obtained from each study patient, comprising bone fragments (sequestrum), necrotic bone pieces, or soft tissue around the inflamed area. Additionally, serum or pus samples were collected from 16 patients (51.7%) with skin abscesses, pus collections, or serous fluid accumulation inside the bone. However, serum or pus samples were not taken from 15 patients (48.3%) due to negative wound drainage and the absence of abscesses or fluid accumulation within the bone.

Pathogens were isolated from 14 out of 31 patients (45.19%), with an equal number of cases found in the thigh and leg, totaling 7 patients each. The remaining 54.81% of cases yielded negative results for pathogen isolation. Specifically, *Staphylococcus aureus* was isolated in 10 patients (32.3%), with 5 cases from the thigh and 5 cases from the leg. *Pseudomonas aeruginosa* was isolated in 2 patients (6.45%), one with chronic bacterial osteomyelitis in the leg and the other in the thigh. Additionally, *Escherichia coli* (*E. coli*) was isolated in one patient (3.22%) with chronic bacterial osteomyelitis in the thigh, and *Klebsiella* was

isolated in one patient (3.22%) with chronic bacterial osteomyelitis in the thigh.

In both groups, 19 out of 31 patients (61.2%) used an external fixator alone without an internal fixator. The average time needed for bone distraction ranged from 30 days to 110 days, depending on the bone defect (2 cm to 10 cm), with an average of 45 days (4.43 cm).

Limb shortening before surgery was present in cases of chronic osteomyelitis in the thigh; 14 patients (73.7%) had an average shortening of 2.5 cm, and 3 patients (25%) with chronic osteomyelitis in the leg had an average shortening of 3.2 cm. Bone grafting was performed in 11 cases in the thigh (57.9%), while it was performed in 4 cases in the leg (33.3%), totaling 15 cases of bone grafting in our study (48.4%).

Patients were followed up for an average of 19.5 months (9 to 30 months) with clinical, radiological, and laboratory tests. In chronic bacterial osteomyelitis in the femur, reinfection occurred in three patients. One of these patients was treated with both external and internal fixation due to a 10-cm bone defect, and the other two were treated with external fixation. These patients had positive bacterial cultures and poorly controlled diabetes. In the case of bacterial chronic osteomyelitis in the tibia, reinfection occurred in one patient, who was treated with both external and internal fixation and had a 5 cm bone defect. Additionally, this patient was a heavy smoker.

Therefore, according to the ASAMI scoring system and Paley et al. (1989), Singh et al. (2019) and (Aktuglu et al. (2019), the bone results in cases of chronic bacterial osteomyelitis in the femur were excellent in 10 patients (52.7%), good in 5 patients (26.3%), fair in 1 patient (5.2%), and poor in 3 patients (15.8%). On the other hand, in cases of the tibia, the bone results were excellent in 10 patients (83.3%) and good in 2 patients (16.7%), and no cases of fair or poor outcomes were recorded.

Table 1: Bone results in our study

Type of Affected Limb	Excellent	Good	Fair	Poor	Total
Chronic Bacterial Osteomyelitis in the Thigh	10	5	1	3	19
Percentage	52.7%	26.3%	5.2%	15.8%	61.3%
Chronic Bacterial Osteomyelitis in the Tibia	10	2	0	0	12
Percentage	83.3 %	16.7 %	0%	0%	38.7 %
Total cases	20	7	1	3	31
Percentage	64.5 %	22.6 %	3.2 %	9.7 %	100 %

The bone results in all cases were excellent in 20 patients (64.5%), good in 7 patients (22.6%), fair in 1 patient (3.2%), and poor in 3 patients (9.7%) (as summarized in Table 1). In the femur, the functional results were excellent in 4 patients (21%), good in 10 patients (52.7%), fair in 2 patients (10.5%), and poor in 3 patients (15.8%). On the other hand, in the

tibia, the functional results were excellent in 8 patients (66.7%) and good in 4 patients (33.3%), while no cases of fair or poor outcomes were recorded. The functional results of the limb in all cases were excellent in 12 patients (38.8%), good in 14 patients (45.1%), fair in 2 patients (6.4%), and poor in 3 patients (9.7%) (as summarized in Table 2).

Table 2: Functional results in our study

Type of Affected Limb	Excellent	Good	Fair	Poor	Total
Chronic Bacterial Osteomyelitis in the Thigh	4	10	2	3	19
Percentage	21%	52.7%	10.5%	15.8%	61.3%
Chronic Bacterial Osteomyelitis in the Tibia	8	4	0	0	12
Percentage	66.7 %	33.3 %	0%	0%	38.7 %
Total Cases	12	14	2	3	31
Percentage	38.8 %	45.1 %	6.4 %	9.7%	100%

Complications

Eight cases of pin tract infection occurred in the thigh, with an additional six cases in the leg. These cases were effectively managed through the cleansing of pin entrances and the administration of prescribed oral antibiotics. The bone distraction phase induced pain in most patients, leading to chronic pain persisting in 6 cases in the thigh and 2 cases in the leg.

Observations revealed three cases of nonunion in the thigh, while the leg saw two cases of delayed union, which were successfully treated with a bone graft. Reinfection was documented in 3 patients in the thigh, and a single case of reinfection occurred in a patient in the leg. Tendon contracture exceeding 15 degrees was observed in the knee in 11 thigh cases, with no occurrences in the leg. Conversely, tendon contracture in the ankle affected 4 cases in the leg, while no cases were noted in the thigh.

Limb deformity exceeding 7 degrees manifested in 8 thigh cases, contrasting with 2 cases in the leg. A severe scar developed in 5 thigh cases and 4 leg cases. Importantly, there were no reported cases of compartment syndrome or any nerve or vascular injuries.

DISCUSSION

Given that a significant proportion of chronic osteomyelitis cases in our study resulted from war-related injuries, particularly in the backdrop of ongoing conflicts in our country, the initial open fractures were severe. They classified in our study

as G2 (7 cases), G3A (7 cases), and G3B (2 cases) based on the Gustilo and Anderson classification (Gustilo and Anderson, 1976; Kim and Leopold, 2012). The treatment methods at the early stage of injury were insufficient or not well thought out, and the failure to treat acute osteomyelitis intensively and effectively contributed to the development of chronic osteomyelitis, ultimately leading to infectious nonunion of the fracture line.

Successfully treating chronic osteomyelitis through antibiotics, basic surgical procedures, or traditional methods is widely acknowledged as a formidable challenge, often resulting in recurring infections (Kanuck and Jolly, 2006). Therefore, an accurate diagnosis of chronic infection must be made, relying on precise clinical features supported by laboratory tests, especially CBC, CRP, and ESR. However, these tests are nonspecific (Lipsky et al., 2012; Kavarthapu and Sánchez, 2023). Radiographic features should also be considered in the diagnosis. Surgical treatment involves meticulous and extensive debridement until oozing, clean bone and bloodied soft tissues are exposed. Samples are taken from soft tissues and necrotic bone to isolate the pathogen, followed by culture and sensitivity testing to select the appropriate antibiotics. Subsequently, a method for reconstructing healthy bone to fill the bone defect is adopted. This often involves using a single-sided external fixation device or the Ilizarov apparatus.

In cases where the bone defect after surgical debridement is substantial, with a length reaching 10 cm in the thigh or 8 cm in the leg, and

considering the potential complications associated with prolonged use of an external fixator alone (such as joint contractures, increased risk of external-to-internal bone infection via fixation pins, and patient intolerance for an extended period) (Kocaoglu et al., 2006), internal fixation is performed in combination with external fixation. This is done especially in cases with negative serological or purulent drainage results and when the bone defect exceeds or equals 2 cm.

The study also explored the impact of smoking and uncontrolled diabetes on the recurrence of chronic osteomyelitis. The results demonstrated a close association between these factors and the likelihood of recurrence (Truntzer et al. 2015; Wang et al., 2017). Furthermore, our study revealed that the number of previous surgeries or interventions for chronic osteomyelitis negatively affects the effectiveness of the surgery performed, and the likelihood of recurrence is higher with an increasing number of previous interventions. Our study had 4 cases of recurrent osteomyelitis out of 31 cases. The first case involved a patient who had undergone nine previous surgical interventions for the infection, focusing on the thigh. The second case involved a patient who had undergone 17 previous surgical interventions for the infection focused on the leg. The third case involved a patient who had undergone 12 previous surgical interventions for the infection focused on the thigh. The fourth case involved a patient who had undergone eight previous surgical interventions for the infection focused on the thigh.

CONCLUSION

Despite the historical challenges of treating chronic bacterial osteomyelitis and its high recurrence rate, adopting a well-structured approach is paramount. This encompasses informed and academic initial management of the primary injury, swift and accurate diagnosis of acute osteomyelitis followed by effective treatment, and mitigating risk factors for the development of chronic osteomyelitis. Key among these risk factors is smoking cessation and maintaining strict glycemic control in diabetic patients. Moreover, achieving a prompt and definitive diagnosis of chronic osteomyelitis, combined with meticulous surgical intervention from the outset involving precise and comprehensive surgical

debridement, pathogen isolation, administration of appropriate antibiotics for a sufficient duration, and thorough bone reconstruction (Rao et al., 2011), whether utilizing an external fixator independently or in conjunction with an interlocking nail, holds the potential to effectively address this demanding and burdensome condition. This comprehensive approach benefits patients and proves advantageous for healthcare professionals. This strategy is a valuable tool in managing chronic bacterial osteomyelitis by preventing limb amputation and enhancing the overall quality of life for affected individuals.

AUTHORS' CONTRIBUTIONS

Haitham Al-Ahmer and Khaled Emara conceptualized and designed the study. Haitham Al-Ahmer performed the orthopedic surgical procedures under Khaled Emara's supervision, while Fouad Al-Daoud analyzed the samples in the hospital laboratory. Haitham Al-Ahmer did the data analysis, while Fouad Al-Daoud assisted in interpreting the results. Haitham Al-Ahmer prepared the original draft (lead) and wrote it. Gohar Mushtaq supported the original draft and scientific improvements in the manuscript. All authors read and approved the final manuscript.

ACKNOWLEDGMENT

This research received no specific grant from any funding agency in the public, commercial, or not-for-profit sectors.

REFERENCES

- Aderibigbe AA, Talabi FO, Adelabu OT, Sanusi BO, Oyinloye O, Adesina OA, et al.; 2024. Influence of Covid-19 protocol messages on patronage of hand sanitisers among undergraduate students. *Pakistan Journal of Life & Social Sciences*, 22(1):33-42.
- Aktuglu K, Erol K, Vahabi A; 2019. Ilizarov bone transport and treatment of critical-sized tibial bone defects: A narrative review. *Journal of Orthopaedics and Traumatology*, 20:1-14.
- Armstrong E, Rush D; 1983. Treatment of Osteomyelitis. *Clinical Pharmacy*, 2(2):213-24.
- Aydingoz U; 2023. Imaging osteomyelitis: An update. *Fortschr Röntgenstr*, 195(04):297-308.

- Azar FM, Canale ST, Beaty JH; 2022. Campbell's operative orthopaedics. Elsevier.
- Burghardt R, Manzotti A, Bhav A, Paley D, Herzenberg J; 2016. Tibial lengthening over intramedullary nails: A matched case comparison with Ilizarov tibial lengthening. *Bone & Joint Research*, 5(1):1-10.
- Carek PJ, Dickerson LM, Sack JL; 2001. Diagnosis and management of osteomyelitis. *American Family Physician*, 63(12):2413-2421.
- Giwanatara G, Hendrawan D; 2021. Juridic review of legal protection for health personnel in radiology in relationship with legal assurance. *Journal of Advances in Humanities and Social Sciences*, 7(2):59-63.
- Gustilo RB, Anderson JT; 1976. Prevention of infection in the treatment of one thousand and twenty-five open fractures of long bones: Retrospective and prospective analyses. *Journal of Bone & Joint Surgery (JBJS)*, 58(4):453-458.
- Hadier SG, Sibtain MA, Yinghai L, Hamdani SMZH, Hamdani SD; 2023. Assessment of the BMI among 8--12-year-old school students stratified by socioeconomic status from Multan, Pakistan: A cross-sectional study. *Journal of Management Practices, Humanities and Social Sciences*, 7(6):39-49.
- Hannan CM, Attinger CE.; 2009. Special considerations in the management of osteomyelitis defects (diabetes, the ischemic or dysvascular bed, and irradiation). In: *Seminars in Plastic Surgery* Thieme Medical Publishers .
- Hatzenbuehler J, Pulling TJ; 2011. Diagnosis and management of osteomyelitis. *American Family Physician*, 84(9):1027-1033.
- Hotchen AJ, McNally MA, Sendi P; 2017. The classification of long bone osteomyelitis: A systemic review of the literature. *Journal of Bone and Joint Infection*, 2(4):167-174.
- Jam FA, Sheikh RA, Iqbal H, Zaidi BH, Anis Y, Muzaffar M; 2011. Combined effects of perception of politics and political skill on employee job outcomes. *African Journal of Business Management*, 5(23):9896.
- Jerzy K, Francis H; 2018. Chronic osteomyelitis-bacterial flora, antibiotic sensitivity and treatment challenges. *The Open Orthopaedics Journal*, 12:153.
- Kanuck D, Jolly G, Mastering complications in external fixation. *Podiatry today*; 2006. <https://shorturl.at/HGi97>.
- Kavarthapu V, Sánchez JA; 2023. Surgical management of diabetic foot infection and osteomyelitis. In: *Functional Limb Salvage: The Multidisciplinary Team Approach*. Springer.
- Kim PH, Leopold SS; 2012. Gustilo-Anderson classification. *Clinical Orthopaedics and Related Research*, 470(11):3270-3274.
- Kocaoglu M, Eralp L, ur Rashid H, Sen C, Bilsel K, et al.; 2006. Reconstruction of segmental bone defects due to chronic osteomyelitis with use of an external fixator and an intramedullary nail. *Journal of Bone & Joint Surgery (JBJS)*, 88(10):2137-2145.
- Lipsky BA, Berendt AR, Cornia PB, Pile JC, Peters EJ, Armstrong DG, et al.; 2012. 2012 infectious diseases society of America clinical practice guideline for the diagnosis and treatment of diabetic foot infections. *Clinical Infectious Diseases*, 54(12):e132-e173.
- Lu V, Zhang J, Zhou A, Krkovic M; 2022. Management of post-traumatic femoral defects with a monorail external fixator over an intramedullary nail. *European Journal of Orthopaedic Surgery & Traumatology*, 32(6):1119-1126.
- Marais LC, Ferreira N, Aldous C, Sartorius B, Le Roux T; 2015. A modified staging system for chronic osteomyelitis. *Journal of Orthopaedics*, 12(4):184-192.
- Messori M, Touloupakis G, Gilli A, Theodorakis E, Pozzi P, Ghirardelli S, et al.; 2023. The risk of infection in open distal tibial fracture: The danger score. *European Journal of Orthopaedic Surgery & Traumatology*, 33(7):2965-2970.
- Nawfal Dagher T, Al-Bayssari C, Diene SM, Azar E, Rolain JM; 2020. Bacterial infection during wars, conflicts and post-natural disasters in

- Asia and the Middle East: A narrative review. *Expert Review of Anti-Infective Therapy*, 18(6):511-529.
- Paley D, Catagni MA, Argnani F, Villa A, Benedetti GB, Cattaneo R; 1989. Ilizarov treatment of tibial nonunions with bone loss. *Clinical Orthopaedics and Related Research (1976-2007)*, 241:146-165.
- Pande KC; 2015. Optimal management of chronic osteomyelitis: Current perspectives. *Orthopedic Research and Reviews*, 2015:71-81.
- Garcia del Pozo E, Collazos J, Carton J, Camporro D, Asensi V; 2018. Factors predictive of relapse in adult bacterial osteomyelitis of long bones. *BMC Infectious Diseases*, 18:1-11.
- Putri EI, Magdalena R, Novamizanti L; 2015. The detection of cervical cancer disease using an adaptive thresholding method through digital image processing. *Journal of Advances in Health and Medical Sciences*, 1(1):30-36.
- Rao N, Ziran BH, Lipsky BA; 2011. Treating osteomyelitis: Antibiotics and surgery. *Plastic and Reconstructive Surgery*, 127:177S-187S.
- Rozbruch SR, Hamdy R, et al.; 2019. *Limb lengthening and reconstruction surgery case atlas*. Springer.
- Saye DE; 2007. Recurring and antimicrobial-resistant infections: considering the potential role of biofilms in clinical practice. *Ostomy/Wound Management*, 53(4):46-8.
- Singh AK, Parihar M, Bokhari S; 2019. The evaluation of the radiological and functional outcome of distraction osteogenesis in patients with infected gap nonunions of tibia treated by bone transport. *Open Access Macedonian Journal of Medical Sciences*, 7(4):559.
- Steinhausen E, Lundin S, Dahmen J, Zulueta La Rosa G, Al Malat T, Glombitza M, et al.; 2016. Validation of the osteomyelitis diagnosis score on the basis of a retrospective analysis of 100 patients with non-union of the Tibia. *Zeitschrift fur Orthopadie und Unfallchirurgie*, 154(6):578-582.
- Subramanyam KN, Mundargi AV, Prabhu MV, Gopakumar K, Gowda DA, Reddy DR; 2023. Surgical management of chronic osteomyelitis: Organisms, recurrence and treatment outcome. *Chinese Journal of Traumatology*, 26(04):228-235.
- Tabakan I, Eser C, Gencil E, Kokaçya Ö; 2021. Reconstruction of firearm and blast injuries in Syrian war refugees. *International Journal of Clinical Practice*, 75(5):e13995.
- Taki H, Krkovic M, Moore E, Abood A, Norrish A; 2016. Chronic long bone osteomyelitis: Diagnosis, management and current trends. *British Journal of Hospital Medicine*, 77(Sup10):C161-C164.
- Taleb ZB, Bahelah R, Fouad FM, Coutts A, Wilcox M, Maziak W; 2015. Syria: health in a country undergoing tragic transition. *International Journal of Public Health*, 60:63-72.
- Townsend O, Koç T; 2023. Diagnosis and management of lower limb osteomyelitis. *Surgery (Oxford)*, 41(4):248-254.
- Truntzer J, Vopat B, Feldstein M, Matityahu A; 2015. Smoking cessation and bone healing: optimal cessation timing. *European Journal of Orthopaedic Surgery & Traumatology*, 25:211-215.
- Wang J, Li S, Meng J, Zhu J, Qiu T, Wang W, et al.; 2022. Baicalin acts as an adjuvant to potentiate the activity of azithromycin against *Staphylococcus saprophyticus* biofilm: an in vitro, in vivo, and molecular study. *Veterinary Research*, 53(1):83.
- Wang Y, Wang J, Deng Z, Jin J, Jiang H, Meng J, et al.; 2017. Chronic osteomyelitis increases the incidence of type 2 diabetes in humans and mice. *International Journal of Biological Sciences*, 13(9):1192.
- Ye Z, Zhao S, Zeng C, Luo Z, Yuan S, Li R; 2021. Study on the relationship between the timing of conversion from external fixation to internal fixation and infection in the treatment of open fractures of extremities. *Journal of Orthopaedic Surgery and Research*, 16:1-9.
- York B, Cha J, Dao A, Gane S, Policinski I, Rahman M, Diagnosis: Chronic osteomyelitis; 2014. <https://shorturl.at/b6cpz>.
- Zimmerli W; 2021. *Bone and joint infections: From microbiology to diagnostics and treatment*. John Wiley & Sons.